

Intense pulsed light source for the treatment of dye laser resistant port-wine stains

P Bjerring, K Christiansen & A Troilius

Authors:

P Bjerring

The Laser Centre, Department of Dermatology, Aarhus University Hospital, Aarhus, Denmark

K Christiansen

Mølholm Medical Research, Private Hospital Mølholm, Vejle, Denmark

A Troilius

Department of Dermatology, University Hospital, Malmö, Sweden

Received 17 April 2002

Accepted 24 January 2003

Keywords:

intense pulsed light source – port-wine stain – treatment – V2 dermatome – vascular malformations

OBJECTIVE: The purpose of this clinical study was to evaluate the efficacy of an intense pulsed light (IPL) irradiator system for the treatment of port-wine stains (PWS) resistant to multiple pulsed dye laser (PDL) treatments.

MATERIALS AND METHODS: Fifteen PWS patients, who were previously found to be resistant to multiple PDL treatments, were treated four times with a second generation IPL system. The clinical efficacy was evaluated on close-up photographs 2 months after the last treatment.

RESULTS: Patients with dye laser resistant PWS could be divided into two groups: responders to IPL treatments (46.7%) and non-responders (53.3%). All responders obtained more

than 50% reduction, and 85.7% of the responders obtained between 75% and 100% reduction of their lesions. The group of non-responders was defined as patients who obtained less than 25% clearance.

CONCLUSIONS: Approximately half of a group of PWS patients, who did not respond to previous PDL treatments, obtained good or excellent clinical effect after four treatments with the IPL system. All PWS, except those located in the V₂ area of the face, responded to the treatments. The IPL treatment modality was found to be safe and efficient for the treatment of PWS, except for those located in the V₂ area.
J Cosmetic & Laser Ther 2003; 5: 7–13

Introduction

Since the late 1970s patients of all ages with port-wine stains (PWS) have been treated with different laser or incoherent light modalities.¹ During the last decade the pulsed dye laser (PDL) has become the most commonly used laser for this purpose, and both safety and efficacy have been evaluated in numerous clinical studies. For example, Alster and Wilson² found a 79% clinical improvement in 76 patients treated for PWS with PDL, and Renfro

and Geronemus³ obtained between 70.7% and 92.4% clearance in 259 patients depending on the anatomical location of the PSW.

Side effects after PDL treatment are well known. Seukeran et al,⁴ in a retrospective study of 701 PWS, found that hyperpigmentation was the most frequently observed side effect with an incidence of 9.1%. Atrophic and hypertrophic scarring was also seen, but only with incidences of 4.3% and 0.7%, respectively.

Katugampola and Lanigan⁵ treated 640 patients with PSW, and for the PWS located in the face 52% of the patients achieved more than 75% fading. The outcome was not correlated to the initial colour of the PWS, and in accordance with the study of Michel et al⁶ the

Correspondence: Peter Bjerring, Department of Dermatology, Aarhus University Hospital, P.P. Ørumsgade 11, DK-8000 Aarhus, Denmark.
Tel: (+45) 40 63 48 78; Fax: (+45) 87 41 51 23

Original Research

final result was unpredictable. A subgroup of PWS were found to be totally resistant to multiple PDL treatment.^{7–11}

The biological effects of PDL treatment of PWS are primarily based on selective photothermolysis,¹² using wavelengths with high absorption in blood (PDL: 575–590 nm) and short pulse durations that confine the tissue damage to the abnormal vessel sizes.¹³ The pulse duration should preferably match the thermal relaxation time of the vessels to be targeted, and theoretical models predict optimal pulse durations from 1 ms to 10 ms for vessels in PWS.¹⁴ Owing to technical reasons, the pulse duration of the first PDLs was fixed at 450 μ s, which is shorter than the theoretically ideal pulse duration. Among other technical and biological variables, this might account for most instances of non-responding PWS. Bernstein¹⁰ successfully treated a resistant PWS with a PDL using a 1.5 ms pulse duration, and Bencini¹⁵ performed double path treatments with both 450 μ s and 1.5 ms PDLs and obtained excellent results in four PWS patients with only three to five treatment sessions. The use of longer wavelengths (600 nm) and correspondingly higher fluences (one and a half to twice the fluency at 585 nm) also showed improvement in PWS clearance, and Edstrom and Ross¹⁶ obtained 20% better lightning of PWS using 600 nm compared to 585 nm PDL treatment.

In contrast to lasers, intense pulsed light (IPL) sources produce variable pulse durations as well as variable wavelength bands and, theoretically, the light emitted from an IPL system may therefore be matched to the absorption coefficient and thermal relaxation time of a broader range of PWS. The clinical efficacy of IPL treatments was investigated by Raulin and Werner¹⁷ in 11 patients with venous malformations. Small lesions (<100 cm²) responded well, and 72% of the patients obtained good or very good (70–100%) clearance after two to three treatments. Alternatively, three large lesions (>100 cm²) were only cleared after an average of 18 sessions. Bleeding, hypopigmentation, hyperpigmentation and scarring were all rare (0.9%).

In the present study, the efficacy of IPL treatments of PDL-resistant PWS was evaluated using an IPL with broadband irradiation (555–950 nm) and long pulse durations (8–30 ms).

Patients and methods

Patients

The study included 15 patients with PWS (9 males and 6 females). The mean age of the patients was 31.2 years (SD: 11.5 years), and the skin types were 1 and 2 (average: 1.6; SD: 0.5) according to the Fitzpatrick phototype scale. All patients were previously treated with up to 15 PDL treatments (average 4.5; SD: 4.1). Treatment sites, PWS colour and size, and light energy used are shown in Table 1. All volunteers gave their written, informed consent, and the regional ethics committee approved the study.

Location	Sex	Age	PWS colour	Area (cm ²)
Arm	Female	22	Purple	90
Neck	Female	38	Pink	60
Neck	Male	27	Purple	45
Neck	Male	22	Purple	60
Neck	Male	37	Purple	45
Trunk	Female	18	Red	200
Face – V ₁	Male	20	Pink	50
Face – V ₂	Male	61	Purple	30
Face – V ₂	Male	28	Pink	30
Face – V ₂	Male	37	Pink	25
Face – V ₂	Female	31	Purple	35
Face – V ₂	Female	27	Purple	15
Face – V ₂	Female	18	Purple	15
Face – V ₂	Male	22	Purple	30
Face – V ₂	Male	47	Purple	30

Table 1

Age and sex distribution of the patients, and size, colour and location of their PWS.

IPL source

An IPL (Ellipse Flex system with a MKII vascular applicator; Danish Dermatologic Development, Hoersholm, Denmark) was used for all treatments. This system produces a single pulse of incoherent light created by a xenon arc flashlamp with pulse durations from 8 ms to 30 ms. The emitted wavelength band was 555–950 nm with the median wavelength of the power spectrum being 705 nm (Figure 1). The filtered light was guided to the skin surface by a light-conducting crystal with an area (footprint on the skin) of 10 × 48 mm.

Experimental procedure

All patients received four IPL treatments with 2-month intervals. The light fluences were individually adjusted in order just to reach the purpura level (range: 13–22 J/cm²) (Table 2). The pulse durations were adjusted between 8 ms and 30 ms according to a clinical assessment of the PWS

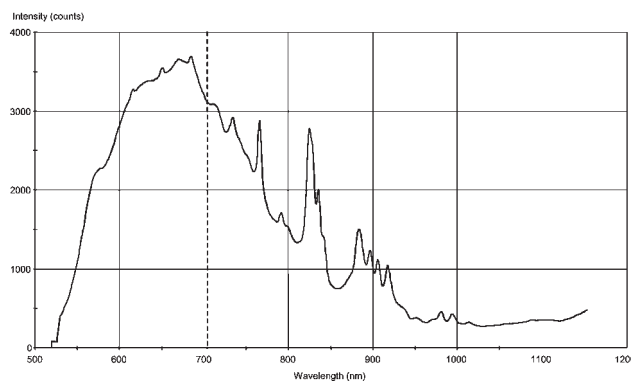


Figure 1

Spectral distribution of IPL energy measured on the skin surface. Median wavelength of the total power spectrum is indicated (dashed line at 705 nm).

Location	Pulse duration (ms)	Energy (J/cm ²)
Arm	8–30	15–18
Trunk	10	17.5–21
Neck	8–10	13–18
Face – except V ₂	8–30	18–20
Face – V ₂	8–18	15–22

Table 2

Treatment parameters for different anatomical locations.

colour because the PWS colour has been shown to correlate with vessel size.¹⁸

Clinical examination and standardized close-up photography were performed before each treatment and at the follow-up visit. The final evaluations of the treatment results were performed by a trained dermatologist in a blinded fashion. The evaluation of efficacy was performed 2 months after the last treatment by dividing the patients into four groups: 0–24%, 25–49%, 50–74% and 75–100% clearance.^{19–21} Patients with clearances of <25% were considered to be non-responders to the IPL treatments.

All patients filled out questionnaires evaluating the clearance, pain level, and their choice of either IPL or PDL treatments, in case further treatments should be performed. The patients were asked to evaluate the clearance according to the four groups given above. The pain level during the IPL treatments was scored by patients on a 100-mm visual analogue scale (VAS), where 0 mm was considered ‘no pain at all’ and 100 mm was considered ‘worst imaginable pain’.

The following side effects were evaluated at the 2-month follow-up: hypopigmentation, hyperpigmentation, atrophic scarring and hypertrophic scarring. All side effects were evaluated on the following scale: none, slight, moderate and severe.

Treatment procedure

Before irradiation, the lesions were covered with a thin layer of transparent hydro-gel (Optical Coupling Gel; Danish Dermatologic Development). The treatments were performed without applying any mechanical pressure to the skin surface in order to avoid expelling blood from the treatment area. A topical group IV glucocorticosteroid was used immediately after the treatments (single application) to reduce immediate inflammatory reactions.

Results

Clearance of PWS

According to the clinical evaluation, the patients could be divided into two groups of nearly equal size (Figure 2). Seven patients (46.7%) responded to the treatment and eight patients did not respond (<25% clearance). The average clearance for all patients was 44.2% (SD: 39.2%).

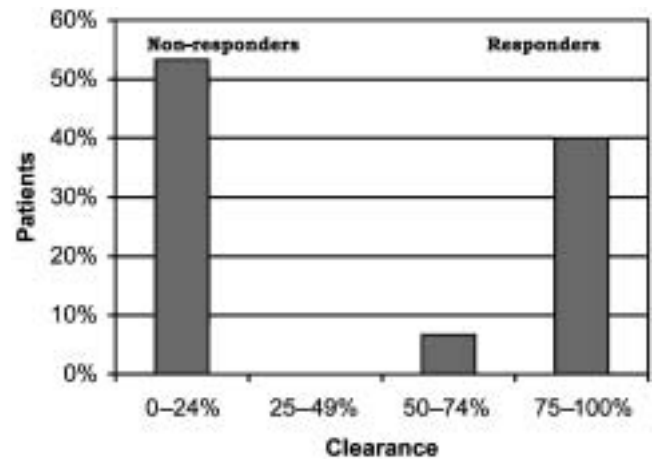


Figure 2

Clearance of PDL-resistant port-wine stains after four IPL treatments.

Patients who previously were resistant to PDL, but responded to subsequent IPL treatment

Among the patients who responded to the IPL treatment, 85.7% had more than 75% clearance and the remaining 14.3% had between 50% and 74% clearance. Examples of the treatment results are shown in Figures 3, 4 and 5.

Patients resistant to both PDL and IPL treatment

Eight patients (53.3%) had less than 25% clearance after the IPL treatments and were considered to be non-responders to IPL treatment (Figure 2). Two of these patients did not obtain any improvement. In all non-responding patients the PWS were located in the central part of the face (V₂ - Second branch of the 5th cranial nerve).

PWS clearance evaluated by the patients

The patients' self evaluations of PWS clearance were more evenly distributed than the objective, blinded, clinical evaluation (Figure 6), and the clearance for all 15 patients was on average evaluated to 46.7% (SD: 21.3%).

Seven (46.6%) of the patients evaluated their personal clearance to be higher than 50%.

Pain level during treatment

The mean pain score registered by the patients was 63 mm (SD: 17 mm) (100-mm VAS). The distribution of pain scores is shown in Figure 7. Fourteen patients (93.5%) would prefer to have IPL treatments performed in the future instead of PDL treatments.

Adverse effects

Immediate side effects. Owing to significant absorption of optical energy in the treated PWS, heat damage and acute inflammation are expected to occur. In all patients, immediate erythema was observed, and variable degrees of edema was observed in all patients – lasting from 2 hours after treatment and up to 5 days. The intended damage of the superficial skin vessels caused leakage

Original Research

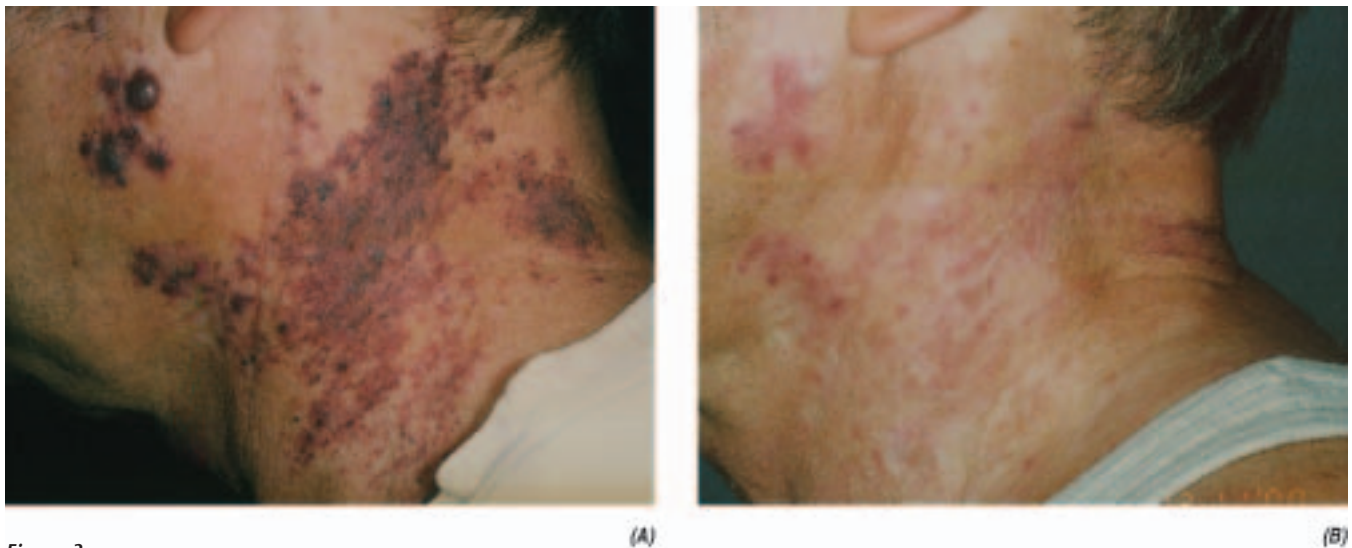


Figure 3

(A) 62 year-old male with PWS located on the neck, previously treated with cryotherapy before IPL treatment. (B) The result after four treatments with 2-month intervals, here shown two month after the final treatment. Depigmentation from previous cryotherapy now visible.

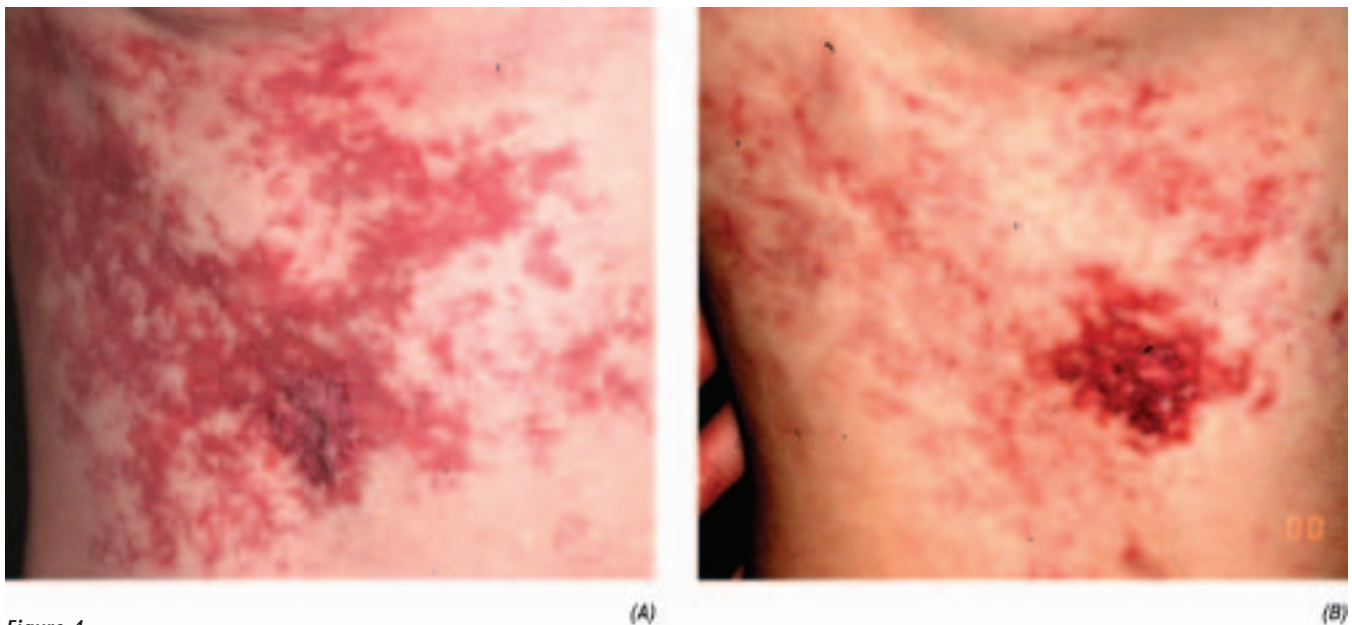


Figure 4

(A) 18 year-old female with a PWS situated on the trunk, before the start of IPL treatments. A circular scarring from earlier PDL treatment is seen in the lower left part of the PWS. (B) The result after four treatments with 2-month intervals, here shown two month after the final treatment. The patient refused to have the earlier PDL treated test spot treated.

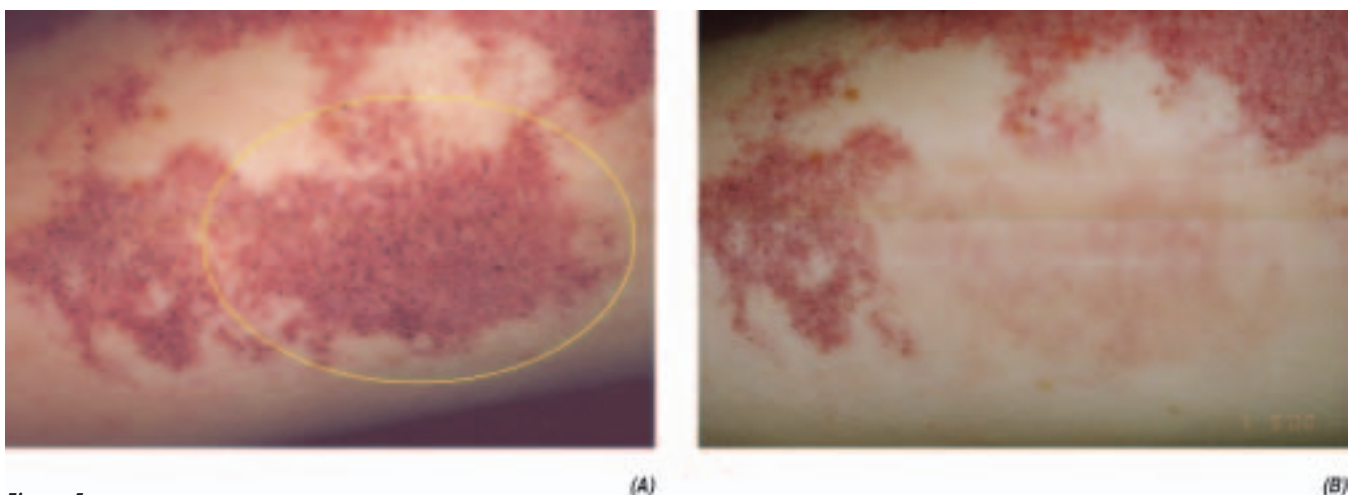


Figure 5

(A) 22 year-old female with a PWS located on the lateral aspect of the upper right arm before treatment. A test spot, marked with a yellow ring, was treated four times with 2-month intervals. (B) The result 2 month after the final IPL treatment.

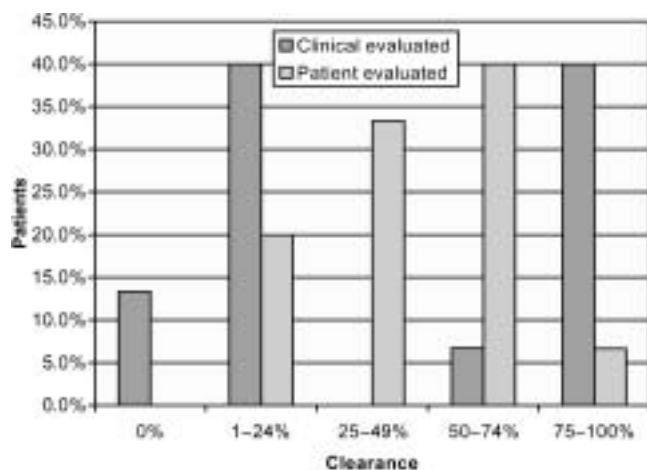


Figure 6
Clearance of PDL-resistant port-wine stains after four IPL treatments evaluated clinically and by the patients.

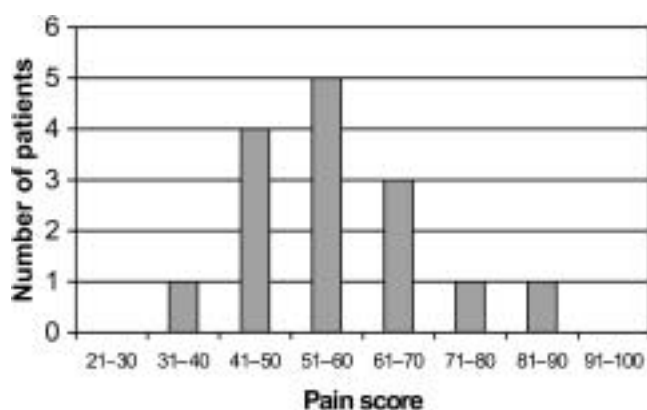


Figure 7
Pain scores based on a 100-mm visual analogue pain score scale (0–100).

of serous fluid leading to crust formation, which disappeared within 10 days. In addition, IPL treatment for vascular lesions on hair-bearing skin theoretically may result in permanent hair removal. This, however, was not observed in any hair-bearing area treated.

Late side effects. Three patients (20%, two responders and one non-responder) developed slight hypopigmentation and one responder (6.7%) had slight hyperpigmentation during the first 2 months after treatment. No hypertrophic scarring was observed. One non-responding patient (6.7%) obtained slight epidermal atrophy.

Discussion

PWS do not involute spontaneously. A total of 83% occur on the face or neck, and the most commonly involved area is the V₂ dermatome (53% of facial PWS).^{22,23} Numerous studies on different treatment parameters and skin pathology have been performed in order to optimize vessel clearance. The final outcome has been found to be dependent on many factors, such as: (1) the applied light energy; (2) the pulse duration; (3) the wavelength or wavelength spectrum; (4) concomitant cooling of the

skin surface^{24,25}; (5) anatomical location and size of the abnormal vessels; and (6) the degree of epidermal melanin concentration.^{26–28}

The lack of clearance of a subset of PDL-treated PWS prompts for investigations into new and improved treatment modalities.^{7–11} In the present study, the IPL technology was used to treat PDL-resistant PWS with a response rate of 46.7% and with an average clearance for the responders of 83.9% (SD: 9.5%). In general, the clinical outcome could be divided into two major groups: either obtaining a very good result or no result at all.

PDL treatment of PWS normally requires multiple sessions to obtain acceptable clearance, and up to 12 treatments sessions are not infrequently encountered.

Seukeran et al⁴ performed an average of 5.5 treatments in 701 patients and Katugampola and Lanigan⁵ treated 75% of 640 patients between six and 12 times. For the patients responding to IPL treatment in the present study we found a clearance >75% in 85.7% of the patients after four treatments. This corresponds well with a retrospective IPL study performed by Raulin et al²⁹ including 37 PWS patients. In that study, clearances of more than 70% were obtained after an average of four treatments for pink lesions, 4.2 for purple lesions and 1.5 for red lesions. These results indicate that the IPL treatments might be a more efficacious treatment modality than the PDL.

In the present study, we did not observe any scarring, which also corresponds with the study on IPL treatments performed by Raulin.²⁹ The occurrence of hypopigmentation and hyperpigmentation seems to be equal for the two treatment modalities, with frequencies of approximately 9% and 3%.^{4,29}

Owing to the built-in dual mode light filter of the present IPL system, only wavelengths from 555 nm to 950 nm reach the skin surface. Since wavelengths longer than 950 nm are filtered out, non-specific heating of the skin can partly be avoided. The fluences used in the study were 13–22 J/cm² (average: 17.5 J/cm², SD: 1.3 J/cm²), which are significantly lower than those reported in other IPL studies where average fluences of 24–80 J/cm² have been used.^{17,29} At these low fluences no epidermal cooling is necessary to avoid side effects.

Normally, skin surface cooling is needed to reduce the pain during IPL treatment, but in the present study 93.5% of the patients preferred IPL treatments to PDL treatments for future treatments.

We found that 53.3% of the patients obtained clearances of <25%. However, in all non-responding patients the PWS was located on the central part of the V₂ dermatome. Treatment of PWS in this location has also previously been reported to be less successful by other investigators.^{22,30,31} For lesions in the central part of the face especially, abnormal vessels are generally located deeper in the skin than in other anatomical sites.^{7,27,32} These vessels require treatments with longer wavelengths with deeper penetration and higher energy levels to compensate for the increased scattering and lower absorption. The relatively short wavelength of the PDL (575–590 nm) might be a reason for the lack of clearance seen in this area. For the IPL system, the wavelength band can be adjusted to match

Original Research

deeper vessels, but still the clinical results are insufficient. In general, the reason for the insufficient clinical results may be that insufficient energy reaches the deeper layers of the skin. Svaasand et al³³ showed in a study of 30 PWS patients that the average vessel diameter for patients with poor responses to PDL treatments was only 19 µm. These vessels are only slightly larger than the normal vessels (12 µm) in the surrounding, normal skin, but significantly smaller than the average diameter of 36–41 µm that was found in PWS responding with good and moderate clearances. The relaxation time for 12-µm vessels is as low as 0.1 ms, and considerably lower than even the PDL pulse duration (0.45 ms). This indicates that the pulse

duration for both IPL (8–30 ms) and for PDL may be too long. Further investigations on IPL treatment of PWS in the V₂ dermatome using pulse durations as short as 1 ms or less should be encouraged.

Conclusions

The present study shows that IPL technology can be used for safe and efficacious treatment of PWS resistant to PDL treatment except for those located in the V₂ area. More than 93% of the patients preferred the IPL to the PDL for future treatments.

References

- Goldberg DJ. Laser treatments of vascular lesions. *Clin Plast Surg* 2000; **27**: 173–80.
- Alster TS, Wilson F. Treatment of port-wine stains with the flash lamp-pumped pulsed dye laser: extended clinical experience in children and adults. *Ann Plast Surg* 1994; **32**: 478–84.
- Renfro L, Geronemus RG. Anatomical differences of port-wine stains in response to treatment with the pulsed dye laser. *Arch Dermatol* 1993; **129**: 182–8.
- Seukeran DC, Collins P, Sheehan-Dare RA. Averse reactions following pulsed tuneable dye laser treatment of port wine stains in 701 patients. *Br J Dermatol* 1997; **136**: 725–9.
- Katugampola GA, Lanigan SW. Five years' experience of treating port wine stains with the flash lamp-pumped pulsed dye laser. *Br J Dermatol* 1997; **137**: 750–4.
- Michel S, Landthaler M, Hohenleutner U. Recurrence of port-wine stains after treatment with the flash lamp-pumped pulsed dye laser. *Br J Dermatol* 2000; **143**: 1230–4.
- Fiskerstrand EJ, Svaasand LO, Kopstad G et al. Photo-thermally induced vessel-wall necrosis after pulsed dye laser treatment: lack of response in port wine stains with small sized or deeply located vessels. *J Invest Dermatol* 1996; **107**: 671–5.
- Lanigan SW. Port-wine stain unresponsive to pulsed dye laser: explanation and solutions. *Br J Dermatol* 2000; **139**: 173–7.
- Verkruyse W, van Gemert MJ, Smithies DJ, Nelson JS. Modelling multiple laser pulses for port wine stain treatment. *Phys Med Biol* 2000; **45**: 197–203.
- Bernstein EF. Treatment of a resistant port-wine stain with the 1.5-msec pulse duration, tuneable, pulsed dye laser. *Dermatol Surg* 2000; **26**: 1007–9.
- Kane KS, Smoller BR, Fitzpatrick RE, et al. Pulsed dye laser-resistant port-wine stains. *Arch Dermatol* 1996; **132**: 839–41.
- Anderson RR, Parrish JA. Microvasculature can be selectively damaged using dye lasers: a basic theory and experimental evidence in human skin. *Lasers Surg Med* 1981; **1**: 263–76.
- Dover JS. New approaches to the laser treatment of vascular lesions. *Australas J Dermatol* 2000; **41**: 14–18.
- Dierickx C, Casparian M, Venugopalan V et al. Thermal relaxation of port-wine vessels probed in vivo: the need for 1–10 millisecond laser pulse treatment. *J Invest Dermatol* 1995; **105**: 709–14.
- Bencini PL. The multilayer technique: a new and fast approach for flashlamp-pumped pulsed (FLPP) dye laser treatment of port-wine stains (preliminary reports). *Dermatol Surg* 1999; **25**: 786–9.
- Edstrom DW, Ross AM. The treatment of port-wine stains with pulsed dye laser at 600 nm. *Br J Dermatol* 1997; **136**: 360–3.
- Raulin C, Werner S. Treatment of venous malformations with an intense pulsed light source (IPLS) technology: a retrospective study. *Lasers Surg Med* 1999; **25**: 170–7.
- Fiskerstrand EJ, Svaasand LO, Kopstad G et al. Laser treatment of port wine stains: therapeutic outcome in relation to morphological parameters. *Br J Dermatol* 1996; **134**: 1039–43.
- Currie CL, Monk BE. Can the response of port-wine stains to laser treatment be reliably assessed using subjective methods? *Br J Dermatol* 2000; **143**: 360–4.
- Lanigan SW. Measuring the improvement in pulsed dye laser treated port wine stains. *Br J Dermatol* 2000; **143**: 241–3.
- Goh CL. Flashlamp pulsed dye laser (585 nm) for the treatment of portwine-stains – a study of treatment outcome in 94 Asian patients in Singapore. *Singapore Med J* 2000; **41**: 24–8.
- Waner M, Suen JY. The treatment of vascular malformations. In: Waner M, Suen JY, eds. *Hemangiomas and vascular malformations of the head and neck*. New York: Wiley-Liss, 1999.
- Troilius A. Treatment of hemangiomas and port-wine stains with emphasis on laser. *Dermatol Ther* 2000; **13**: 17–23.
- Chan HH, Chan E, Kono T et al. The use of variable pulse width frequency doubled Nd:YAG 532 nm laser in the treatment of port-wine stain in Chinese patients. *Dermatol Surg* 2000; **26**: 657–61.
- Ries WR, Speyer MT, Reinisch L. Effects of thermal conducting media on the skin surface during laser irradiation. *Laryngoscope* 2000; **110**: 574–84.
- Sommer S, Sheehan-Dare RA. Pulsed dye laser treatment of port-wine stains in pigmented skin. *J Am Acad Dermatol* 2000; **42**: 667–71.
- Fiskerstrand EJ, Svaasand LO, Volden G. Pigmentary changes after pulsed dye laser treatment in 125 northern European patients with port wine stains. *Br J Dermatol* 2000; **138**: 477–9.
- Fiskerstrand EJ. Laser treatment of port wine stains. A study of efficacy and limitations of the pulsed dye laser Trondheim: The Norwegian University of Science and Technology, 1999 (PhD Thesis).

29. Raulin C, Schroeter CA, Weis RA et al. Treatment of port-wine stains with noncoherent pulsed light source: a retrospective study. *Arch Dermatol* 1999; **135**: 679–83.
30. Troilius A, Svendsen G, Ljunggren B. Ultrasound investigation of port-wine stains. *Acta Derm Venereol* 2000; **8**: 196–9.
31. Nguyen CM, Yohn JJ, Huff C et al. Facial port wine stains in childhood: prediction of the rate of improvement as a function of the age of the patient, size and location of the port wine stain and the numbers of treatments with the pulsed dye (585 nm) laser. *Br J Dermatol* 2000; **138**: 821–5.
32. Eubanks LE, McBurney EI. Videomicroscopy of port-wine stains: correlation of location and depth of lesion. *J Am Acad Dermatol* 2001; **44**: 948–51.
33. Svaasand LO, Fiskerstrand EJ, Kopstad G, Norvang LT. Therapeutic response during pulsed laser treatment of port-wine stains: dependence on vessel diameter and depth in dermis. *Lasers Med Sci* 1995; **10**: 235–43.